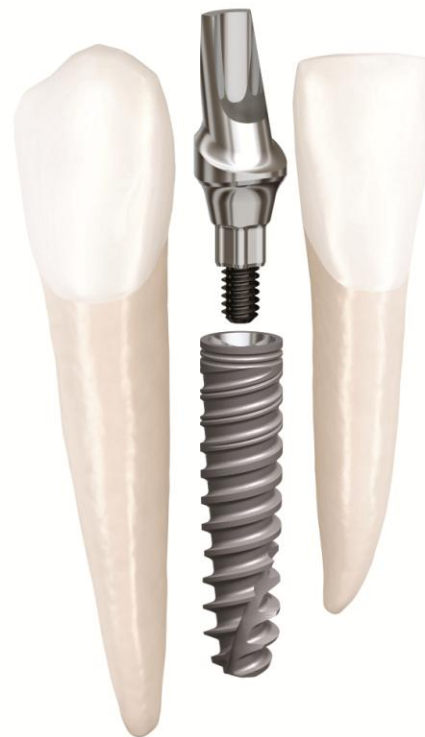

Clinical Case

NobelActive® 3.0

January, 2012




NobelActive[®] 3.0



Dr. Scott MacLean

Canada



Lower lateral incisor restoration

Male patient

19 years old

Implant:

NobelActive 3.0 3.0 x 11.5mm

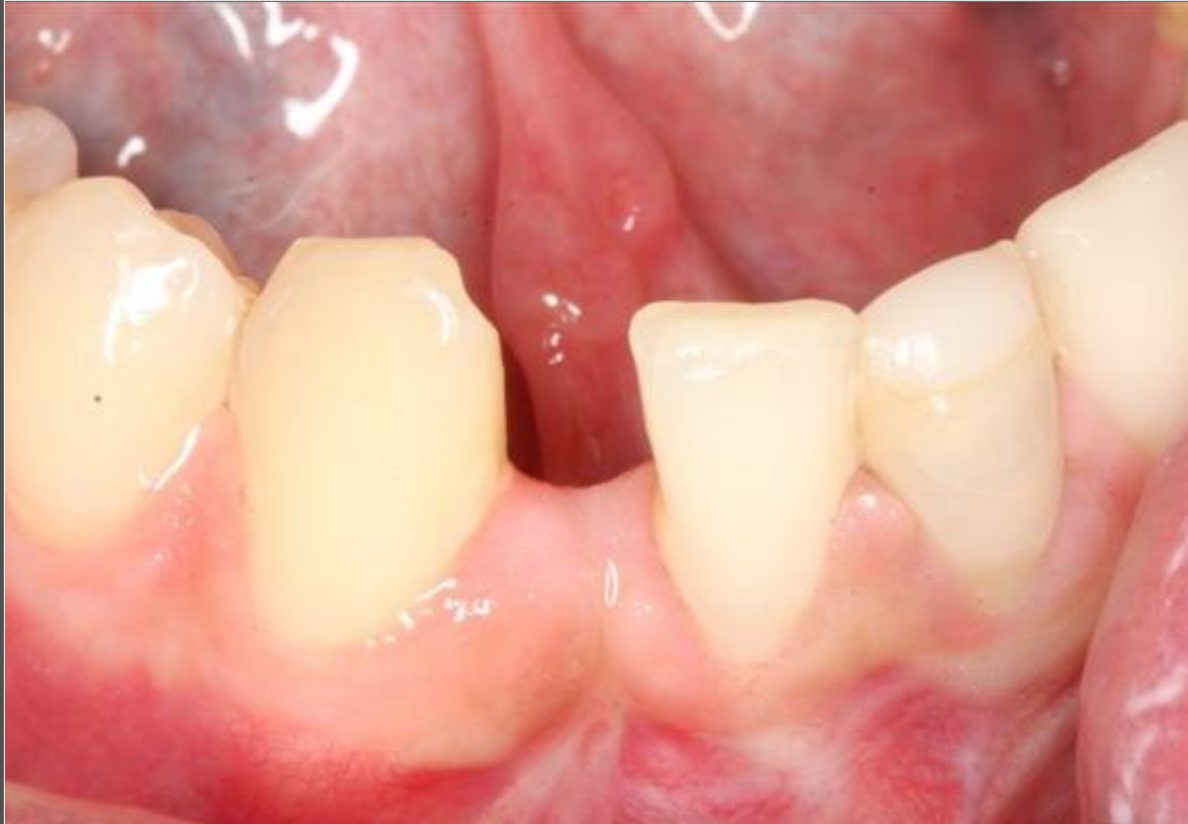Surgery date:

March 11th, 2011

Flapless

FDI POS: tooth 42

NobelActive[®] 3.0

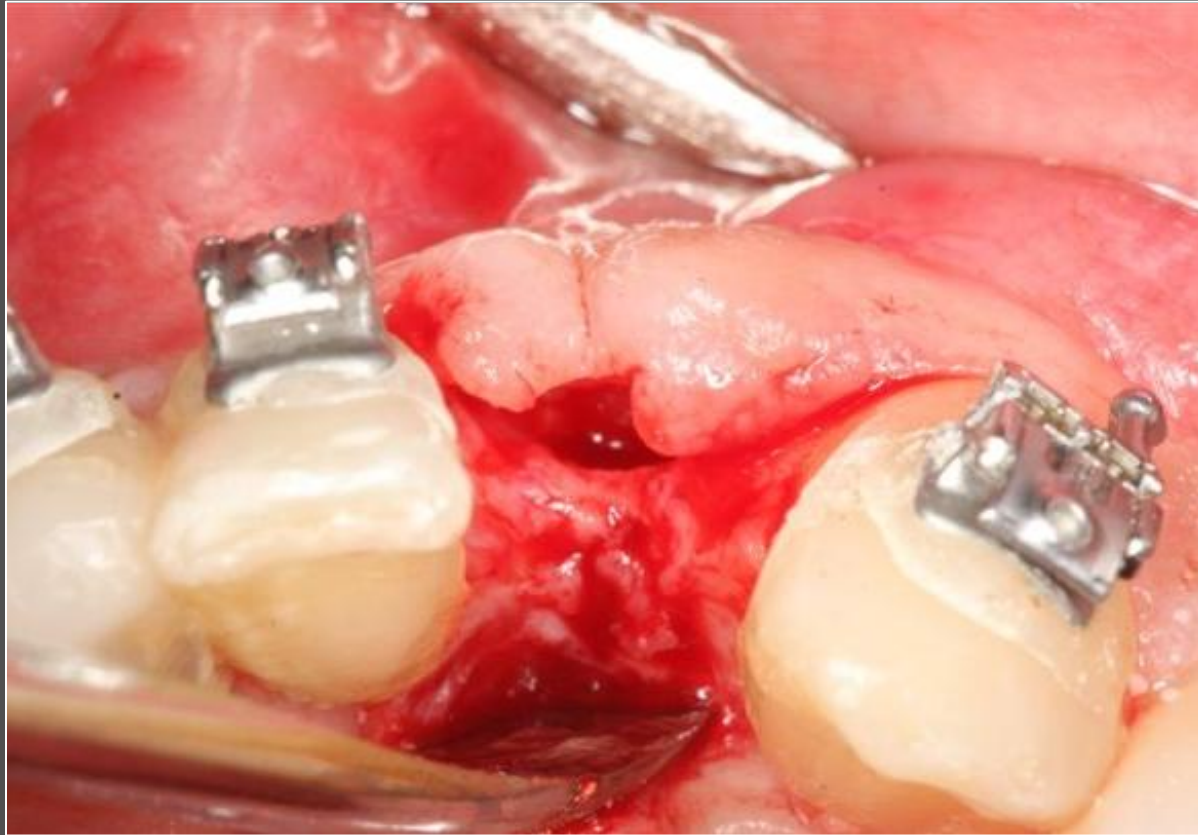


Initial clinical situation:

Trauma case, before orthodontic treatment

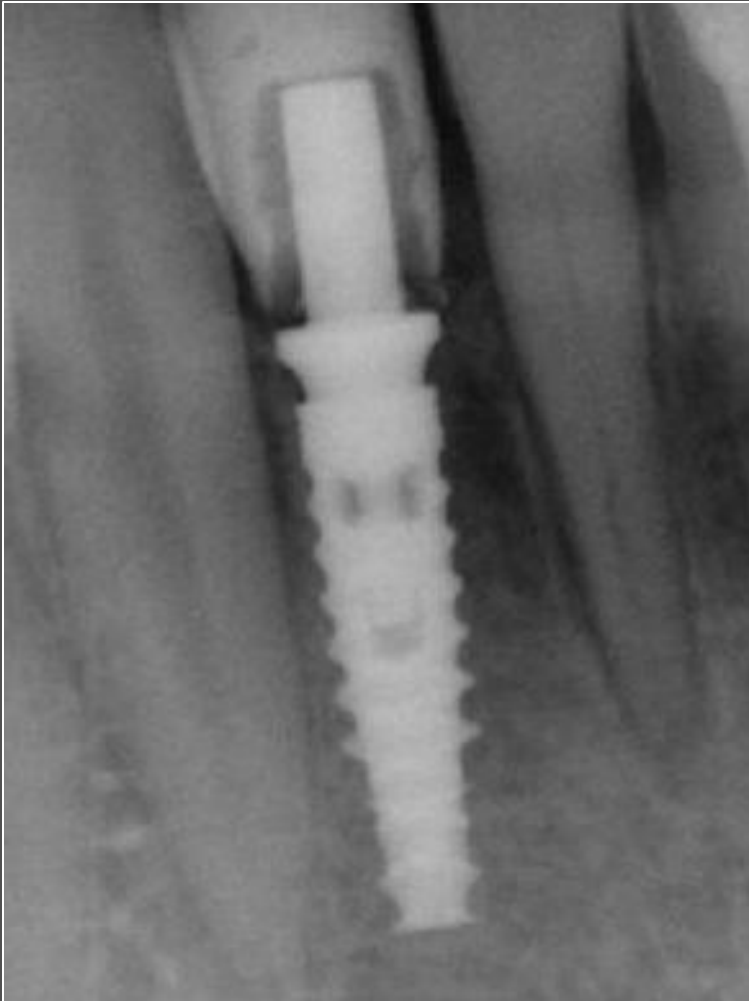
Courtesy of Dr. Scott MacLean

NobelActive[®] 3.0



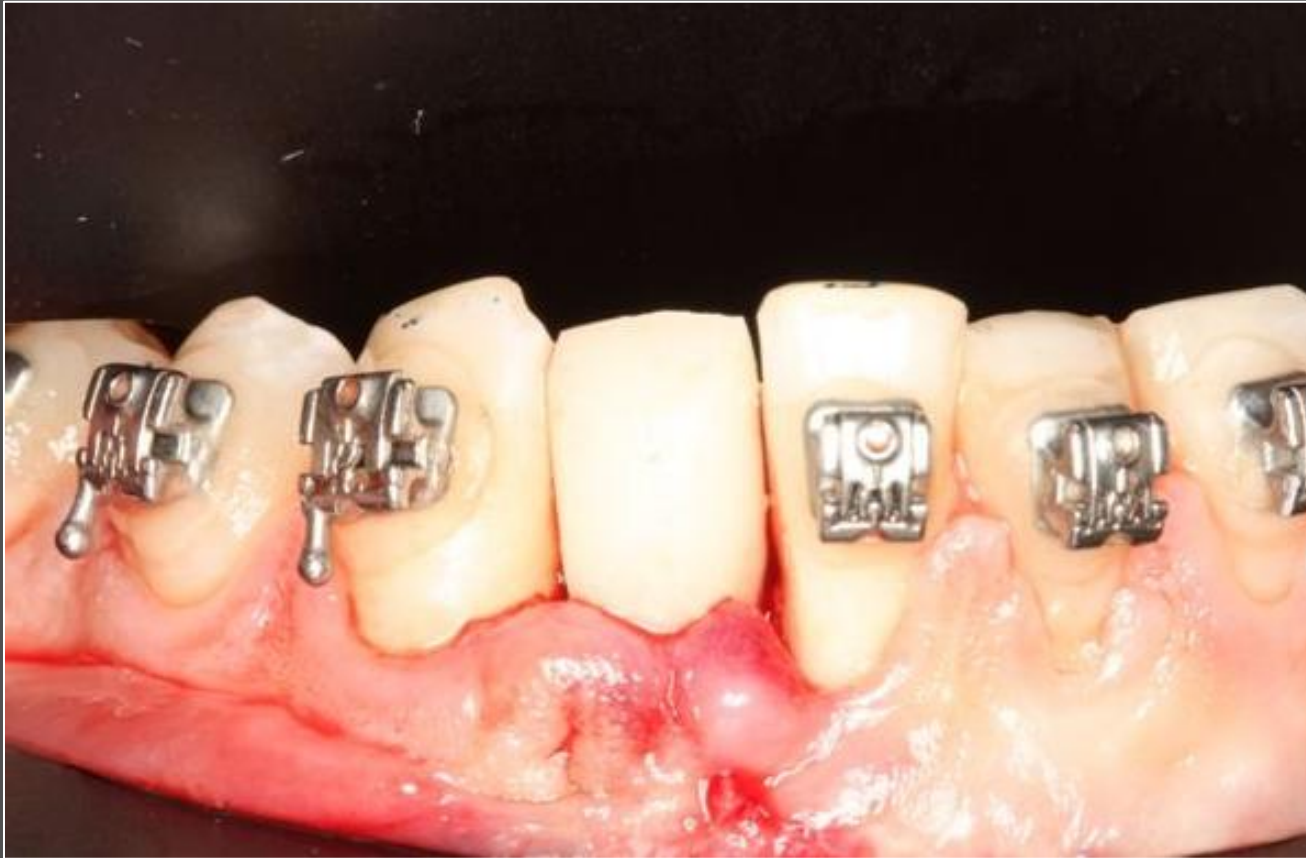Implant surgery after orthodontic treatment. Very thin ridge.

NobelActive[®] 3.0



Radiograph: implant insertion

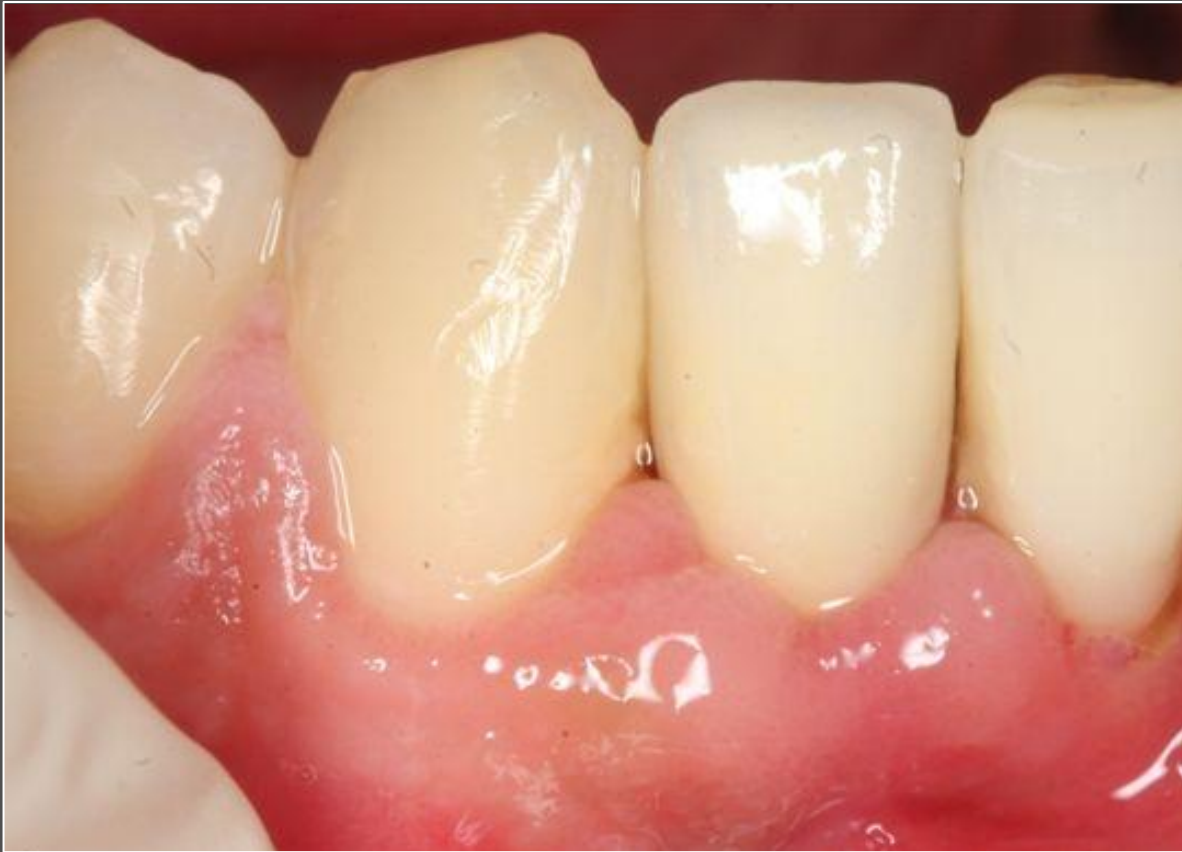NobelActive[®] 3.0



Temporary restoration on Immediate Temporary Abutment immediately after surgery.

Courtesy of Dr. Scott MacLean

NobelActive[®] 3.0



Definite restoration in place.