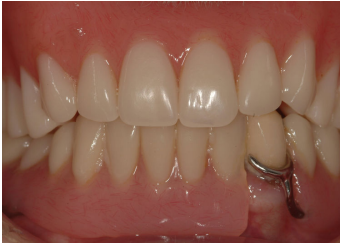

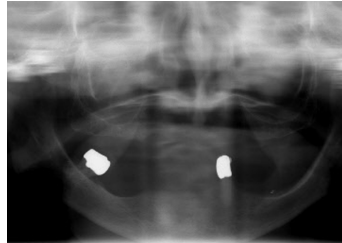
Edentulous Solutions – Mild Bone Resorption

Mandibular Rehabilitation with Implant Supported Overdenture

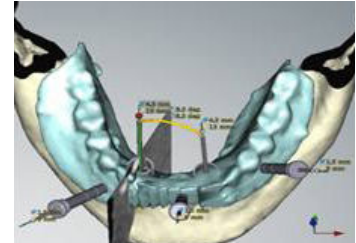
Patient: A 92-year old woman came for a consultation with a chief complaint of bad fitting prosthesis with decreased stability especially while eating. They were made 3 months ago. **Overall Health:** Very good. Hip replacement performed 5 years ago. No medication. **Oral examination:** 2 remaining teeth, with one molar and one canine in the mandible. The existing prosthesis was neither ideal nor stable and the occlusal plane needed corrections. **Decision:** Extraction of the remaining teeth. In maxilla, a conventional denture was advised. In mandible, placement of 2 implants with Locator Abutments and a new implant retained overdenture was the treatment selected. NobelClinician software was used for the implant treatment planning and NobelGuide protocol for the flapless implant placement with a delayed loading was the treatment of choice. **Total treatment time:** 6 months



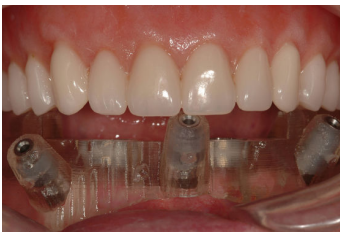Initial examination shows an unstable prosthesis with decreased retention, making it difficult for the patient to eat.



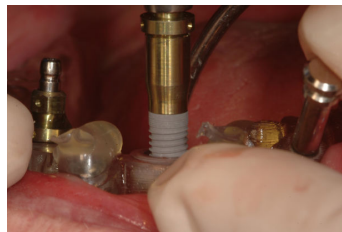
Pre-op radiograph shows moderate bone resorption in the maxilla and posterior mandible; a mild bone resorption in the anterior mandible was observed.



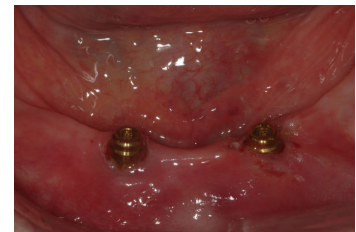NobelClinician software used as an aid for treatment planning, digital diagnosis and final positioning of the implants.



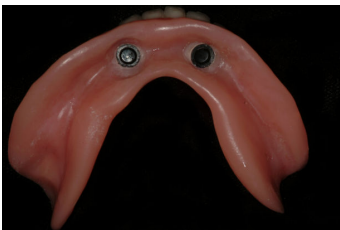Surgical Template used for guided implant placement and predictable transferring of implant planning into clinical reality.



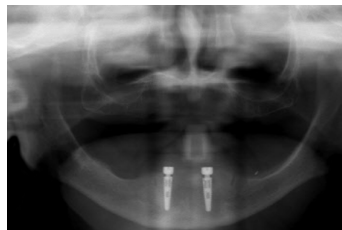
NobelGuide protocol used for the insertion of 2 NobelReplace Tapered Groovy Implants with Healing Abutments directly after a flapless surgery.



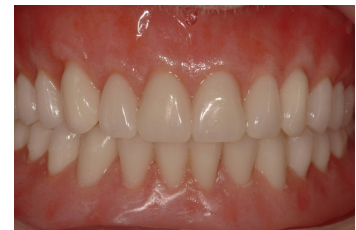2 Locator Abutments in position waiting for the final prosthesis to be delivered.



Locator Denture Caps with Locator Black Processing Cap (Male) embedded in the prosthesis.



Post-op radiograph shows both implants placed parallel to reduce excessive stress on the Locator Abutments.



New denture in the maxilla and an implant supported overdenture in the mandible for an ideal occlusion and function.